ATHENA HEART CARE

Dr. Manoj J Pradhan
Consultant Cardiothoracic Surgeon
Dr. Alka M Pradhan
Consultant Cardiac Anaesthesiologist

MR. RADHE SHYAM MITTAL
PRN : 113258 Age/Sex 58 Yrs / Male
Visit : IP-1 Dt. : 30/03/2019 00:30
Consultant : Dr. D Gaware

Mr. Mittal
CABG x 4 - BHS / GRAH HAMS

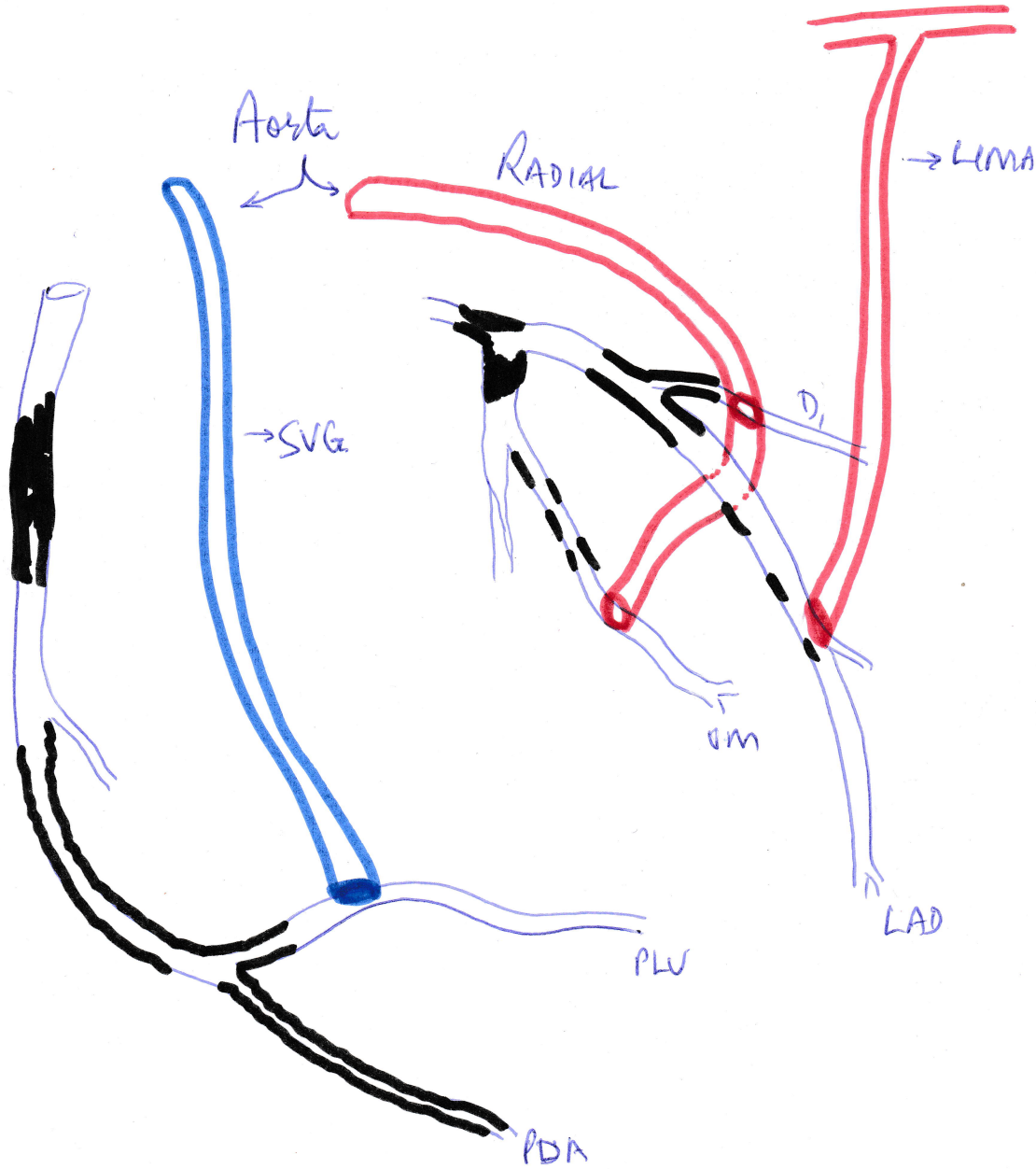

NOTE: This is only a schematic representation of the coronary anatomy and the grafts !!

DR.MANOJ. J. PRADHAN
MS MCh
CARDIOTHORACIC SURGEON
NM Wadia Hospital Pune

159, Sohrab Hall, Sassoon Rd., Pune. Tel.No: - 020-26059722, 26059100

OPERATION NOTE

NAME– Mr. Mittal Radheshyam M **DATE –03/04/2019** **REG NO –**

TYPE OF OPERATION: CABG x 4 – BHS + IABP +ERAH

SURGEON: Dr. Manoj Pradhan **Assistant surgeon: Shivalli**

ANAESTHETIST: Dr.Alka Pradhan **Cardiologist:** D B Gaware

INDICATION OF SURGERY– Unstable angina,LMCAD+TVD,EF 35%,Ongoing angina+hi enzymes-IABP x 36 hrs

SUMMARY -LIMA-LAD, LIMA-RAY, RA – D1+OM+PLV, Ao – SVG-PDA

CPB Details – Guidant HS Auto transfusion ERAH

VESSEL	SIZE	SHUNT	QUALITY	CONDUIT	SITE OF ANASTOMOSIS	INOTROPES
LAD	2.0mm	1.75mm	sw plaque	LIMA e - s	Distal third	Dopamine 3.0 mcg/kg/min Adrenaline 0.15 mcg/kg/min Noradrenaline 0.01mcg/kg/min
PLV	1.75mm	1.50mm	sw plaque	SVG (e-s)	Proximal	Dopamine 3.0 mcg/kg/min Adrenaline 0.05 mcg/kg/min Noradrenaline 0.05 mcg/kg/min
Dr	2.00mm	1.75mm	Sw + bw plaque	RADIAL (s-s)	Proximal	Dopamine 3mcg/kg/min Adrenaline 0.05mcg/kg/min Noradrenaline 0.01mcg/kg/min
OM	1.75mm	1.50mm		RADIAL (e-s)	Proximal	Dopamine 3mcg/kg/min Adrenaline 0.05mcg/kg/min Noradrenaline 0.05mcg/kg/min

DRAINS: 2, 1 L pleural, 2 RV wires

Remarks: PDA heavily diseased – ungraftable, vessels small & diseased, LV hypertrophic.